

# Mesenchymal Stem Cells and Stromal Vascular Fraction for Hair Loss

## Current Status



Gorana Kuka Epstein, MD<sup>a,b,c,\*</sup>, Jeffrey S. Epstein, MD<sup>d,e,f</sup>

### KEYWORDS

- Adipose-derived stem cells • Hair loss • Androgenic alopecia • Stromal vascular fraction
- Regenerative cell therapy

### KEY POINTS

- Regenerative therapy has an expanding role in the treatment of various forms of alopecia.
- A review of the literature confirms the beneficial results of various cell therapies for such conditions as male and female androgenic alopecia and scarring alopecia.
- Adipose tissue allows for safe and easy access to regenerative cells and stromal vascular fraction and appears to be a low-risk harvesting procedure.
- The authors' experience shows positive indications for using purified fat and hair transplantation in certain hair loss conditions.

### INTRODUCTION

Mesenchymal stromal cells (MSCs) are undifferentiated cells that are able to renew their population and become differentiated to produce all specialized cell types of the tissue from which they originate.<sup>1,2</sup> Apart from traditionally being isolated from the bone marrow, the first tissue from which stem cells were identified, MSCs have also been found in many other tissues, such as liver, cord blood, placenta, dental pulp, and adipose tissue.<sup>2</sup> Adipose-derived stromal cells (ADSCs) are easier to isolate and provide a higher number of stromal cells than bone marrow tissue.<sup>3</sup>

The main roles of MSCs are to maintain the stem cell niche, facilitate recovery after injury, and

ensure homeostasis of organs and tissues.<sup>4</sup> ADSCs can differentiate into mesenchymal lineage cells but also secrete various cytokines and growth factors that have paracrine effects on surrounding cells: vascular endothelial growth factor (VEGF), hepatocyte growth factor (HGF), insulin-like growth factor (IGF), platelet-derived growth factors (PDGF), and others.<sup>5,6</sup> These factors seem to play a role in neovascularization, which is important in a variety of hair loss conditions.

Androgenic alopecia (AGA) remains the main cause of hair loss in both men and women.<sup>7,8</sup> The 2 medicines currently approved by the Food and Drug Administration for the treatment of AGA are finasteride (for men only) and minoxidil. Both carry untoward side effects and lack consistent efficacy.<sup>9,10</sup>

Disclosure: The authors have nothing to disclose.

<sup>a</sup> BelPrime Clinic, Department for Hair Restoration "Hair Center Serbia", Brane Crncevica 16, 11000 Belgrade, Serbia; <sup>b</sup> Department of Research, Foundation for Hair Restoration, 6280 Sunset Drive, Suite 504, Miami, FL 33143, USA; <sup>c</sup> Department of Research, Foundation for Hair Restoration, 60e 56th Street, New York, NY 10021, USA; <sup>d</sup> Foundation for Hair Restoration, 6280 Sunset Drive, Miami, FL 33143, USA; <sup>e</sup> Foundation for Hair Restoration, 6280 Sunset Drive, Suite 504, Miami, FL 33143, USA; <sup>f</sup> Foundation for Hair Restoration, 60e 56th Street, New York, NY 10021, USA

\* Corresponding author. 6280 Sunset Drive, Suite 504, Miami, FL 33143.

E-mail address: gorana.kuka@me.com

Facial Plast Surg Clin N Am 26 (2018) 503–511

<https://doi.org/10.1016/j.fsc.2018.06.010>

1064-7406/18/Published by Elsevier Inc.

## THE AUTHORS' RATIONALE

In the authors' earliest work with adipose tissue, they saw its distinct potential as an adjunct in hair transplantation surgery in the reconstruction of scalp scars. The growth of hair follicles transplanted into scars is usually lower than in normal scalp because of a thick collagen pattern and compromised blood supply in scar tissue. The authors' method is to pretreat scalp scars with autologous adipose tissue injections and then perform the hair transplant procedure 3 months later. Early on in their work, the authors were encouraged by the finding that during the creation of recipient sites into which the hair grafts would be inserted, the scar tissue would usually bleed more than untreated scar tissue, a benefit of the angiogenesis that took place due to the addition of adipose tissue. This pretransplant fat transfer technique was applied successfully in treating scars of a variety of causes: burns, chemical injury, surgical injury, physical trauma, and congenital scar conditions (Fig. 1).

Based on the authors' observed benefits in these scar tissue cases, they decided to apply fat grafting for the treatment of AGA. Theoretically,

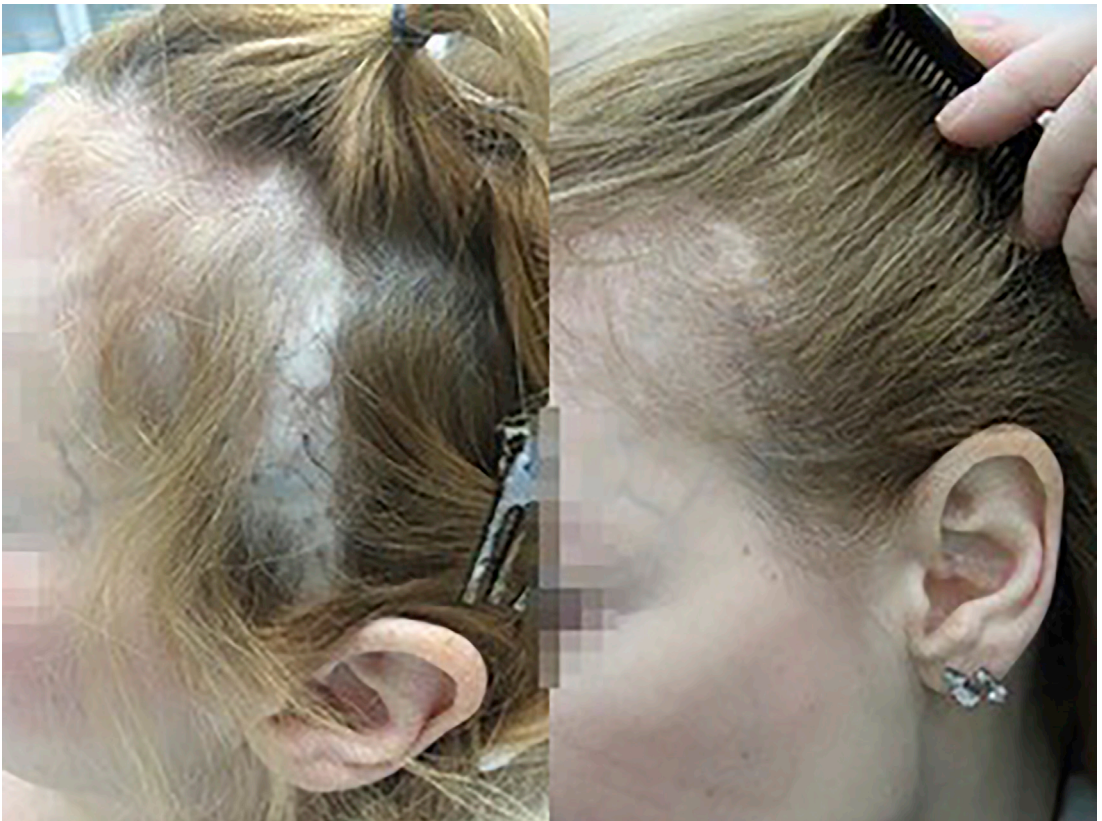adipose tissue could have the following beneficial effects.

### Anti-inflammatory Effect

Many scarring and nonscarring types of alopecia have some degree of underlying inflammation. Mild perifollicular fibrosis and infiltrates have also been found in patients with androgenetic alopecia.<sup>11</sup> ADSCs may prevent further inflammation and possible damage to hair follicles through the enhancement of antioxidative and anti-inflammatory mechanisms. Their anti-inflammatory and immunomodulatory properties are reflected in their potential to inhibit maturation and production of cytokines and to impair the cytotoxic potential of natural killer cells and T lymphocytes.<sup>12</sup> Furthermore, ADSCs are able to inhibit the proliferation of B cells and their capacity to produce antibodies.<sup>12</sup>

### Antiandrogen Effect

Areas affected with hair loss have higher levels of dihydrotestosterone (DHT), an androgen that causes hair loss. Finasteride decreases levels of DHT but also has potential side effects. The antiandrogen effect of adipose tissue derives from the



**Fig. 1.** A patient whose chemical injury in the temporal areas was pretreated with fat injections and then 3 months later underwent a hair transplant procedure.

isoenzyme aldo-keto reductase 1G2 (AKR1G2), which inactivates androgens by converting potent DHT into weak 3- $\alpha$  diol through 3- $\alpha$  reductase activity.<sup>13</sup> When injected into an area affected by hair loss, adipose tissue could exert an antiandrogen effect without systemic effects.

### ***Re-creating Thickness of the Scalp***

Hori and colleagues<sup>14</sup> published a paper 50 years ago that examined the variation in thickness of balding versus nonbalding scalp. It was observed that the thickness of the subdermis remains the same in early stages of male pattern baldness (MPB) and decreases sharply in advanced stages. This thinning of the adipose layer is a landmark of aging scalp, because it was even more notable in cadavers. By the injection of additional fat into the balding areas, a fuller subdermal layer of fat can be created, critical for the optimal growth of hair follicles, as well as to prevent its complete loss. Adipocytes act as a niche for hair follicles, increasing the skin's thickness and advancing the intradermal adipocyte layer during the anagen phase of hair growth that may counteract the hypothesis that the telogen phase may be due to an absence of adipose tissue, with the literature indicating that hair and adipose loss occur together. In addition, ADSCs and adipocytes regulate the hair cycle via the release of signaling molecules, that is, WNTs, platelet derived growth factors (PDGF), bone morphogenic proteins (BMPs), and fibroblast growth factors (FGFs).<sup>15</sup>

### ***Mesenchymal Stem Cells***

The paracrine characteristics of ADSCs may include the specific factors released by them, including VEGF, HGF, IGF, and PDGF, that have possible effects on hair regeneration.<sup>16</sup> There have been attempts to augment adipose retention and increase its survival on injection, limiting the need for repeat procedures. Zhu and colleagues<sup>17</sup> in an animal model showed improved retention of adipose tissue injected with cells versus adipose tissue alone at 6 and 9 months. Therefore, enriching adipose tissue with ADSCs could extend the benefits in treating hair loss.

### ***Neovascularization***

One myth about hair loss is that it is caused by poor blood circulation in the scalp. Although no scientific studies have been done, this poor circulation may in fact not be a myth but an important factor due to the decrease in the supply of blood that provides oxygen and nutrients to hair follicles. Several studies have shown that adipocytes can induce angiogenesis. Yuan and colleagues<sup>18</sup> presented

that ADSCs may induce new blood vessel growth around and into the fat graft by releasing significant amounts of angiogenic growth factors, such as VEGF, HGF, basic fibroblast growth factor (bFGF). Magalon and colleagues,<sup>19</sup> in a study treating scleroderma patients with adipose-derived stromal vascular fraction (ADSVF) injections, noted that ADSVF may improve vasomotor tone and microvascular perfusion, which is consistent with one of the main properties of ADSVF, the promotion of vascular repair and angiogenesis.<sup>4,20</sup>

## **REVIEW OF THE LITERATURE**

Although many studies have been published on hair regeneration using ADSCs in either cultured hair follicles or animal models, there have been only a few published on their application in human subjects. The authors searched PubMed up to November 2017 using terms related to hair regeneration: MSCs, ADSCs or ADSC-CM, alopecia, hair loss, restricted to human studies. Fukuoka and colleagues<sup>21</sup> were the first to use adipose-derived stem cell-conditioned medium (ADSC-CM) (AAPE; Prostemics, Seoul, Korea) in 22 patients (11 men and 11 women) injected intradermally every 3 to 5 weeks for 6 sessions. The ADSC-CM was delivered with a 31-gauge needle to provide 0.02 mL/cm<sup>2</sup> of solution with a total of 3 to 4 mL injected. Finasteride was administered to 6 of the 11 male patients. Trichograms were taken before and then 7 to 12 months after the initial treatment. Ten of the 22 patients had a half-side comparison study, receiving ADSC-CM treatment on the left side and placebo (saline injection) treatment on the right. The mean increase in number of hairs was  $29 \pm 4.1$  in men and  $15.6 \pm 4.2$  in women, with no significant difference observed between the finasteride and nonfinasteride group. In the half-side comparison study, the number of hairs was significantly higher in the treated versus placebo side.

In 2017, Fukuoka and colleagues<sup>22</sup> conducted another study with the same medium in 21 patients (16 men and 5 women) whereby injections were done in the same manner. After 3 months, there was a reported increase in the number of hairs from baseline of  $141.2 \pm 31.4$  in men and  $109.8 \pm 43.5$  in women. Also reported was that patients were often able to notice changes in hair quality and in reduction in area of the extent of thinning hair through photographs after 4 to 5 treatments. Similar to the prior study, 10 patients had a half-side comparison study, whereby saline was injected as a placebo. There was a significant difference in increased hair counts between the treatment and placebo sides ( $18.4 \pm 9.4$  vs  $6.5 \pm 11.7$ ).

Shin and colleagues<sup>23</sup> published a retrospective case study on the clinical use of the same media of adipose tissue-derived stem cells in female pattern hair loss by analysis of patient medical records and phototrichographic images. This retrospective observational study of outcomes in 27 patients with female pattern hair loss treated with ADSC-CM showed efficacy after 12 weeks of therapy. Hair density increased from 105.4 to 122.7 hairs per squared centimeter, whereas hair thickness increased from 57.5 to 64.0  $\mu\text{m}$ .

Shin and colleagues<sup>11</sup> assessed the effect of ADSC-CM in AGA in a study of 27 women and 25 men. Patients received ADSC-CM by micro-needle roller or mesotherapy gun weekly for 12 weeks and were followed for 1 year. After 12 weeks of therapy, hair density increased from 105.4 to 122.7 counts per squared centimeter, whereas mean hair thickness increased from 57.5 to 64.0  $\mu\text{m}$ . In men specifically, this hair density increased from 97.7 to 108.1 counts per squared centimeter, and mean hair thickness increased from 65.4 to 71.8  $\mu\text{m}$ . These effects were maintained for the full year, and no severe adverse reactions were reported. This study had a split-scalp study subgroup on 6 patients with MPB, using ADSC-CM on the test side and the same medium without ADSCs as a control. After 12 weeks of therapy, the total hair count in a circle 1 cm in diameter was significantly higher on the treated side ( $P = .0010$ ); however, the mean hair diameter did not significantly differ between the sides.

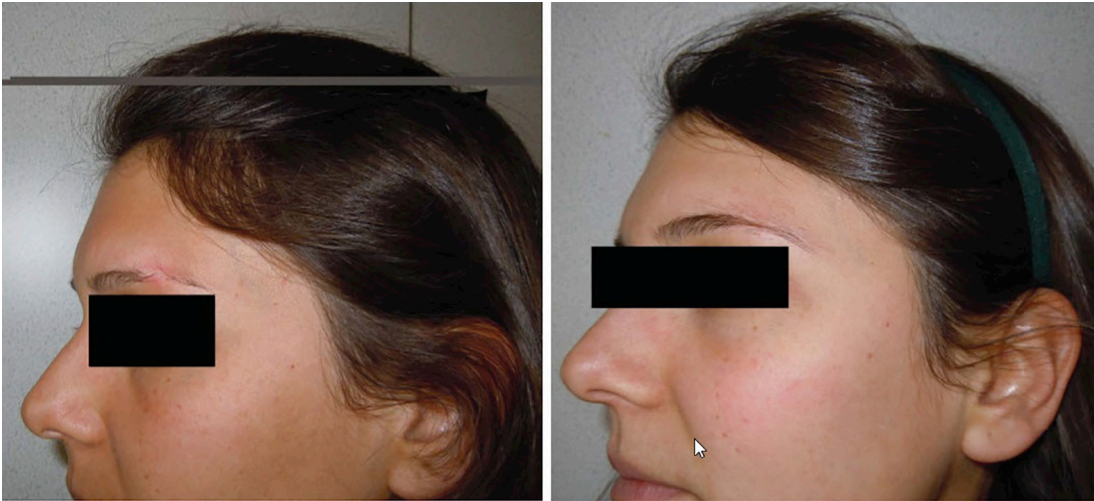Apart from ADSC-CM application, there was one study whereby stromal vascular fraction (SVF) with autologous adipose tissue was done in 9 patients (8 men and 1 woman).<sup>24</sup> The SVF was obtained from lipoaspirate processed by the Kerastem Celution System (Kerastem LLS, Solana Beach, CA, USA), whereas adipose tissue was purified by the Puregraft system (Puregraft LLC, Solana Beach, CA, USA) and injected separately. The mixture of adipose tissue, SVF, and lactated Ringer solution was injected in a fanlike pattern in the subcutaneous layer of the scalp using a 1.0-mL Luer Lock syringe attached to a 1.2-mm cannula to apply 1.0 mL of the mixture per square centimeter of scalp. One patient was treated with adipose injections only, whereas a split-scalp procedure was done using saline injection as a control. All male patients were in the Norwood 3 stage of hair loss, whereas no staging was available for the female patient. Follow-up was done by global photography, and macrophotography was done using the FotofinderMediscope Selective System, with results analyzed by Fotofinder System TrichoScale software (Fotofinder,

Columbia, MD, USA). Six-month follow-up data were available for 6 patients. In patients who received fat plus SVF, a mean increase of 31 hairs per squared centimeter (23% relative percentage increase) was documented, whereas in the one subject who received fat alone a mean increase of 14 hairs per squared centimeter of scalp was noted. In one split-scalp patient, the treatment area had an increase of 44.1 hairs per squared centimeter of scalp compared with the area receiving placebo that had a mean increase of 1.33 hairs per squared centimeter. Despite some limitations of the study (small sample size, poor follow-up data, nonblinded analysis), this initial study shows that SVF with fat injection is a safe and promising alternative approach to treating hair loss in men and women.

Apart from treating AGA, Dini and colleagues<sup>25</sup> presented a case of a female patient with alopecia areata of the left eyebrow treated with autologous fat transplantation. A marked improvement was noted in the atrophic scar, while hair regrowth was observed at 3 months (Fig. 2). Cho and colleagues<sup>26</sup> described a case of a woman suffering from scleroderma-induced atrophic alopecia who presented with a 3  $\times$  4-cm alopecic patch on the frontal scalp. Two fat injections were performed 3 months apart, and hair growth was noticed 3 months after the second treatment.

Gentile and colleagues<sup>27</sup> published a study on treating 23 patients with androgenetic alopecia Norwood 3 to 5 with isolated stem cells from human follicles (HFSCs). Cells were isolated with a device called the Rigenaracons (CE certified class I; HBW srl, Turin, Italy) that disaggregates a strip of scalp from the back of the head (the usual "donor" area for a hair transplant, an area where hair follicles are not affected by DHT) under sterile conditions in 1.2 cc of physiologic solution. After 60 seconds of centrifugation at 80 rpm, a cell suspension was obtained and injected into the scalp by an Ultim gun (Anti-Aging Medical Systems, Montrodat, France) in 2 sessions spaced 60 days apart. Apart from the treatment area, another zone served as a control (saline injections). Follow-up was done by global, but not standardized, photography. Twenty-three weeks after the treatment, a 29%  $\pm$  5% increase in hair density was noted compared with a less than 1% increase noted in the placebo area. It is unclear how the increase in hair count was determined because no macrophotography was done. However, on global photographs, an improvement can be noted. This study is the first with HFSCs that showed a positive therapeutic effect on male AGA.

Zanzottera and colleagues<sup>28</sup> conducted a pilot study to assess the application of the same cellular



**Fig. 2.** A patient with alopecic eyebrow before and 3 months after adipose tissue injections. (From Dini M, Mori A. Eyebrow regrowth in patient with atrophic scarring alopecia treated with an autologous fat graft. *Derm Surg* 2014;40(8):926-8; with permission.)

suspension in its impact on wound healing and survival of transplanted hairs after a hair transplant procedure. At the conclusion of the hair transplant procedure, the adipose tissue recovered from the discarded donor material during graft preparation was processed using the Rigenera system (Human Brain Wave srl, Torino, Italy). This cell suspension was then injected subcutaneously and spread out over the recipient sites before and after the graft insertion. Three subjects were monitored after 5 days, 2 weeks, and 1 month. Two weeks after the procedure, healing of the microwounds was complete, and the hair continued growing, atypical after most hair transplant procedures, where the transplanted hairs typically fall out before starting to regrow 3 to 4 months later. The investigators also reported a low level of pain and edema in these patients. This study is a very small study, and more complete clinical work is necessary to better determine if and how this cell suspension improves hair transplantation results.

## CURRENT STUDIES

A search of the terms “stem cells” and “hair loss” on [www.clinicaltrials.gov](http://www.clinicaltrials.gov) resulted in reporting 6 studies using SVF to treat either AGA or alopecia areata (**Table 1**).

The only study completed to date is STYLE-Transplantation of Cell Enriched Adipose Tissue For Follicular Niche Stimulation in Early Androgenetic Alopecia. This trial was a randomized, blinded, controlled, multicentered trial wherein 71 subjects, men and women, were randomized into 4 groups: Puregraft fat enriched with high dose

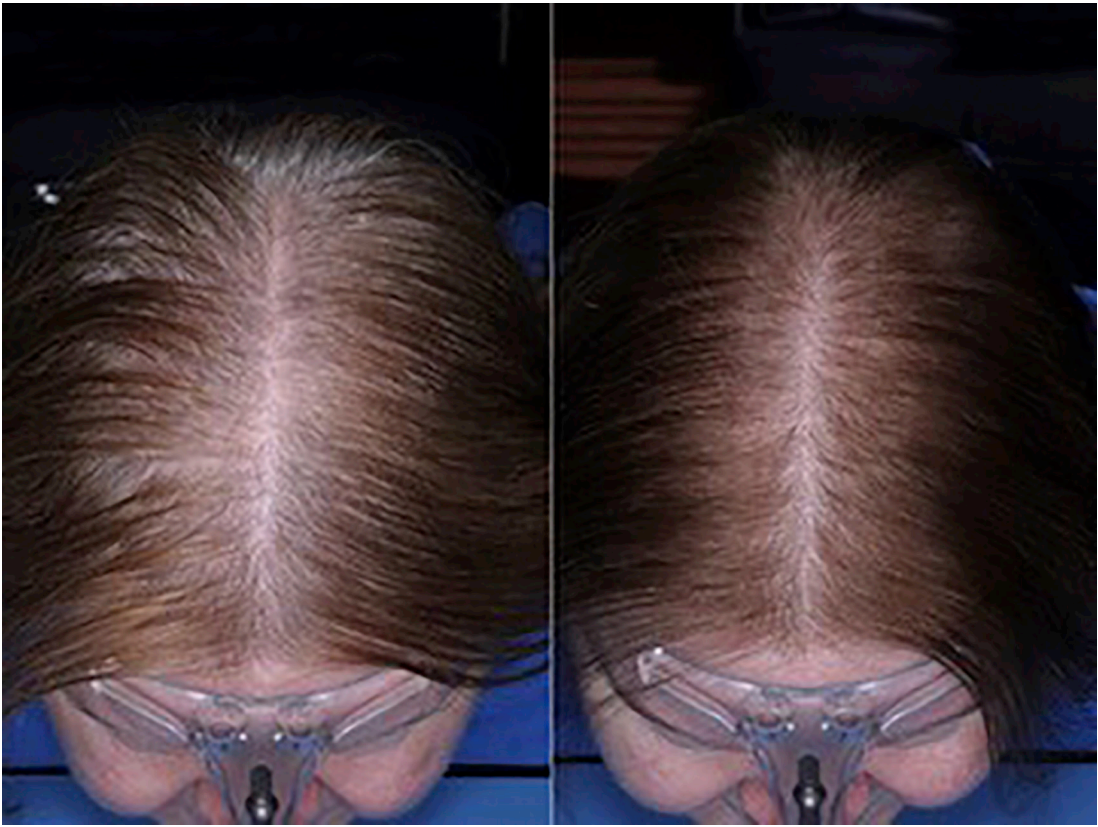
of adipose-derived regenerative cells (ADRCs,  $1.0 \times 10^6/\text{cm}^2$ ), Puregraft fat enriched with low dose of ADRCs ( $0.5 \times 10^6/\text{cm}^2$ ), Puregraft fat alone, and saline injections only, in the ratio of 2:2:2:1. ADRCs were obtained by Kerastem Celution device (Kerastem LLS), from the patient's own adipose tissue, while fat was purified by the Puregraft system (Puregraft LLC). The fat was delivered into the subdermal layer by cannula ( $0.1 \text{ mL}/\text{cm}^2$ ), and the cells were delivered by 22-gauge needle injections ( $0.1 \text{ mL}/\text{cm}^2$ ) into a  $40\text{-cm}^2$  sized area. Follow-up was done by global and macrophotography at weeks 6, 12, 24, and 52. Although data through week 52 are still pending, the 24-week results were presented by the first author of this article at the International Society of Hair Restoration Surgery Annual Meeting in Prague in October 2017.<sup>29,30</sup> At 24 weeks, there was an absolute mean change in terminal hairs from baseline of 29 hairs per squared centimeter, compared with control (a 16% point delta) in men with Norwood Class 3 hair loss who received Puregraft fat enriched with low-dose ADRCs. No serious adverse events occurred.

## AUTHORS' EXPERIENCE

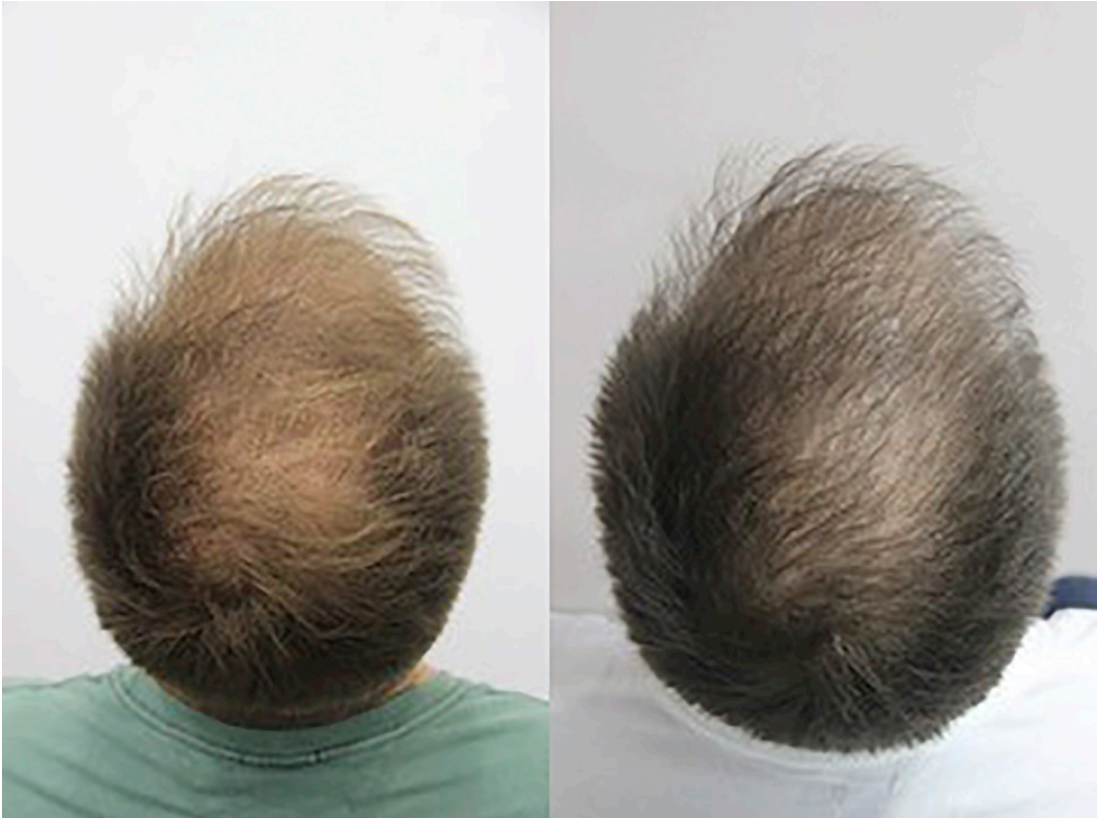Although the regulation on the use of SVF in the United States is still pending, the authors of this article began applying adipose injections for various types of alopecias. The authors are treating both men and women with either adipose tissue injections alone or with a 4:1 mixture of adipose tissue to platelet-rich plasma (PRP). To date, this therapy has been applied to conditions

Table 1 Current studies listed on www.clinicaltrials.gov on the use of stromal vascular fraction to treat androgenic alopecia or alopecia areata					
Study Title and Trial Number	Conditions	Interventions	Outcome Measures	Number Enrolled	Locations
Stem Cell Educator Therapy in Alopecia Areata NCT01673789	Alopecia areata	Device: stem cell educator	Feasibility and efficacy of stem cell educator therapy in alopecia areata	30	The First Hospital of Hebei Medical University Shijiazhuang, Hebei, China
The Effect of Allogeneic Human Adipose-Derived Stem Cell Component on Androgenic Alopecia NCT02594046	AGA	Other: stem cell component extract	Change of total hair counts by phototrichogram	38	
Adipose Tissue-Derived Stem Cell-Based Hair Restoration therapy for Androgenetic Alopecia NCT02865421	Hair restoration using autologous mesenchymal stem cells	Drug: stem cells Drug: PRP	Pull test Trichoscan	88	
Biocellular-Cellular Regenerative Treatment Scarring Alopecia and Alopecia Areata NCT03078686	Alopecia areata Scarring areata	Procedure: tSVF by lipoaspiration Procedure: PRP concentration Procedure: emulsification tSVF	Safety of intervention hair growth assessment Photographic assessment scalp hair	60	<ul style="list-style-type: none"> <li>• Kenneth Williams, DO Irvine, CA, USA</li> <li>• Regeneris, Medical North Attleboro, MA, USA</li> <li>• Regenevita LLC Stevensville, MT, USA</li> </ul>
Point-of-Care Adipose-Derived Cells for Hair Growth NCT02729415	Androgenetic alopecia	Procedure: SVF cells Procedure liposuction Other: hair measurements	<ul style="list-style-type: none"> <li>• Incidence of treatment-emergent adverse events</li> <li>• Growth of new hair from baseline to 6 wk, 3 mo, and 6 mo</li> <li>• Change in hair thickness from baseline to 6 wk, 3 mo, and 6 mo</li> </ul>	8	<ul style="list-style-type: none"> <li>• University of Florida, Gainesville, FL, USA</li> </ul>
AGA Biocellular Stem/Stromal Hair Regenerative Study NCT02849470	Hair disease	<ul style="list-style-type: none"> <li>• Procedure: intradermal injection in hair loss</li> <li>• Procedure: PRP</li> <li>• Procedure: adipose-derived stem/stromal cells</li> </ul>	<ul style="list-style-type: none"> <li>• Safety-tolerability assess of SAE/AE assessment of SAE/AES</li> <li>• Hair growth trichogram</li> <li>• Hair density trichogram</li> </ul>	60	<ul style="list-style-type: none"> <li>• Kenneth Williams, DO, Irvine, CA, USA</li> </ul>

Abbreviations: AE, adverse event; AES, adverse events; SAE, serious adverse events; tSVF, tissue stromal vascular fraction.



**Fig. 3.** A 57-year old female patient with hair loss treated by adipose tissue injections.



**Fig. 4.** A 28-year old male patient with hair loss treated by adipose tissue injections.

such as AGA, frontal fibrosing alopecia, lichen planopilaris, and alopecia totalis. The authors' method consists of harvesting fat with liposuction and processing it with the Puregraft system and then injecting it by cannula into the subcutaneous layer of the scalp. An amount of 0.1 to 0.2 cc of fat is injected per squared centimeter, and in certain conditions where scarring is encountered, there is a physical role of the cannula movements in breaking up the fibrous tissue, which is then further improved by the addition of the adipose tissue. Although still in the stage of collecting data, this therapy has proven to be safe, with improvements in overall appearance of the hair documented with photography (**Figs. 3 and 4**).

## SUMMARY

Adipose tissue, as the easiest accessible source of mesenchymal stem cells, has emerged as a new therapeutic option for hair loss. The regenerating effects of ADSC-CM have been demonstrated by several clinical studies. Adipose-derived stem cells offer a huge potential for hair regeneration. It is up to future studies to establish more definitive protocols not only in the isolation of ADSCs but also in its application and answer dilemmas on their effectiveness. Based on initial work and the science behind it, the authors believe there is a definite potential for this therapy.

## REFERENCES

1. Tabatabaei Qomi R, Sheykhasan M. Adipose-derived stromal cell in regenerative medicine: a review. *World J Stem Cells* 2017;9(8):107–17.
2. Marquez-Curtis LA, Janowska-Wieczorek A, McGann LE, et al. Mesenchymal stromal cells derived from various tissues: biological, clinical and cryopreservation aspects. *Cryobiology* 2015; 71:181–97.
3. Sheykhasan M, Qomi RT, Ghiasi M. Fibrin scaffolds designing in order to human adipose-derived mesenchymal stem cells differentiation to chondrocytes in the presence of TGF- $\beta$ 3. *Int J Stem Cells* 2015;8:219–27.
4. Rehman J, Traktuev D, Li J, et al. Secretion of angiogenic and antiapoptotic factors by human adipose stromal cells. *Circulation* 2004;109:1292–8.
5. Kinniard T, Stabile E, Burnett MS, et al. Narrow-derived stromal cells express gene encoding a broad spectrum of arteriogenic cytokines and promote in vitro and in vivo arteriogenesis through paracrine mechanisms. *Circ Res* 2004;94:678–85.
6. Whiting DA. Scalp biopsy as a diagnostic and prognostic tool in androgenetic alopecia. *Dermatol Ther* 1998;8:24–33.
7. Otberg N, Finner AM, Shapiro J. Androgenetic alopecia. *Endocrinol Metab Clin North Am* 2007;36(2): 379–98.
8. Dinh QQ, Sinclair R. Female pattern hair loss: current treatment concepts. *Clin Interv Aging* 2007; 2(2):189–99.
9. Ross EK, Shapiro J. Management of hair loss. *Dermatol Clin* 2005;23(2):227–43.
10. Mysore V. Finasteride and sexual side effects. *Indian Dermatol Online J* 2012;23(2):227–43.
11. Shin H, Won CH, Chung WK, et al. Up-to-date clinical trials of hair regeneration using conditioned media of adipose-derived stem cells in male and female pattern hair loss. *Curr Stem Cell Res Ther* 2017;12(7):524–30.
12. Zhao S, Wehner R, Bornhäuser M, et al. Immunomodulatory properties of mesenchymal stromal cells and their therapeutic consequences for immune-mediated disorders. *Stem Cells Dev* 2010;19(5): 607–14.
13. O'Reilly MW, House PJ, Tomlinson JW. Understanding androgen action in adipose tissue. *J Steroid Biochem Mol Biol* 2014;143:277–84.
14. Hori H, Moretti G, Rebora A, et al. The thickness of human scalp:normal and bald. *J Invest Dermatol* 1972;6:396–9.
15. Festa E, Fretz J, Berry R, et al. Adipocyte lineage cells contribute to the skin stem cell niche to drive hair cycling. *Cell* 2011;146(5):761–71.
16. Anderi R, Makdissy N, Rizk F, et al. Hair quality improvement in alopecia patients following adipose-derived stem cell treatment. *JPRAS Open* 2017.
17. Zhu M, Zhou Z, Chen Y, et al. Supplementation of fat grafts with adipose –derived regenerative cells improves long-term graft retention. *Ann Plast Surg* 2010;64:222–8.
18. Yuan Y, Gao J, Liu L, et al. Role of adipose-derived stem cells in enhancing angiogenesis early after aspirated fat transplantation: induction or differentiation? *Cell Biol Int* 2013;37(6):547–50.
19. Magalon G, Daumas A, Sautereau N, et al. Regenerative approach to scleroderma with fat grafting. *Clin Plast Surg* 2015;42:353–64.
20. Nakagami H, Maeda K, Morishita R, et al. Novel autologous cell therapy in ischemic limb disease through growth factor secretion by cultured adipose tissue-derived stromal cells. *Arterioscler Thromb Vasc Biol* 2005;25:2542–7.
21. Fukuoka H, Suga H. Hair regeneration treatment using adipose-derived stem cell conditioned medium: follow-up with trichograms. *Eplasty* 2015;15:e10.
22. Fukuoka H, Narita K, Suga H. Hair regeneration therapy using proteins secreted by adipose-derived stem cells. *Curr Stem Cell Res Ther* 2017; 12:531–4.
23. Shin H, Ryu HH, Kwon O, et al. Clinical use of conditioned media of adipose tissue-derived stem cells in



- female pattern hair loss: a retrospective case series study. *Int J Dermatol* 2015;54(6):730–5.
24. Perez-Meza D, Ziering C, Sforza M, et al. Hair follicle growth by stromal vascular fraction-enhanced adipose transplantation in baldness. *Stem Cells Cloning* 2017;10:1–10.
  25. Dini M, Mori A, Quattrini Li A. Eyebrow regrowth in patient with atrophic scarring alopecia treated with an autologous fat graft. *Dermatol Surg* 2014;40(8):926–8.
  26. Cho SB, Roh MR, Chung KY. Recovery of scleroderma-induced atrophic alopecia by autologous fat transplantation. *Dermatol Surg* 2010;36:2061–3.
  27. Gentile P, Scioli MG, Bielli A, et al. Stem cells from human hair follicles: first mechanical isolation for immediate autologous clinical use in androgenetic alopecia and hair loss. *Stem Cell Investig* 2017;4:58.
  28. Zanzottera F, Lavezzari E, Trovato L, et al. Adipose derived stem cells and growth factors applied on hair transplantation follow-up of clinical outcome. *J Chem Dermatol Sci Appl* 2014;4:268–74.
  29. Kuka Epstein G, Epstein J, Washenik K, et al. Transplantation of cell enriched adipose tissue for follicular niche stimulation in early androgenetic alopecia. Presented at annual meeting of the International Society of Hair Restoration Surgery ISHRS meeting, Prague, Check Republic, 2017.
  30. Li Y, Yan B, Wang H, et al. Hair regrowth in alopecia areata patients following Stem Cell Educator therapy. *BMC Med* 2015;13:87.